

Eugenol Protection of Testicular Function in Diabetic Rats by Attenuating Oxidative Stress and Restoring *CatSper* Gene Expression



Maryam Shaeghi Rad¹ , Nasim Hayati Roodbari^{1*} , Amir Afshin Khaki^{2*} , Akram Eidi¹ , Fardin Amidi³

1. Department of Biology, SR.C., Islamic Azad University, Tehran, Iran.

2. Department of Anatomical Sciences, Faculty of Medicine, Tabriz University of Medical Sciences, Tabriz, Iran.

3. Department of Anatomical Sciences, Faculty of Medicine, Tehran University of Medical Sciences, Tehran, Iran.



Citation Shaeghi Rad M, Hayati Roodbari N, Afshin Khaki A, Eidi A, Amidi F. Eugenol Protection of Testicular Function in Diabetic Rats by Attenuating Oxidative Stress and Restoring *CatSper* Gene Expression. *Research in Molecular Medicine*. 2025; 13(2):107-116. <https://doi.org/10.32598/rmm.13.2.1446.1>

 <https://doi.org/10.32598/rmm.13.2.1446.1>

Article Type:

Research Paper

Article info:

Received: 05 Feb 2025

Revised: 27 Feb 2025

Accepted: 10 Apr 2025

Keywords:

Diabetes mellitus (DM), Infertility, Male, Eugenol, Oxidative stress, *CatSper*, rat, Antioxidants, Spermatogenesis

ABSTRACT

Background: Diabetes mellitus (DM) frequently leads to male infertility, with oxidative stress being a primary culprit in damaging testicular function. This damage may extend to key spermatogenic genes, including the sperm-specific cation channels *CatSper1* and *CatSper2*, which are essential for male fertility.

Materials and Methods: This study investigated the therapeutic potential of eugenol against testicular dysfunction in a streptozotocin (STZ)-induced diabetic rat model, focusing on glycemic control, oxidative stress, histopathology, and the expression of *CatSper1* and *CatSper2* genes. In this experimental study, 32 male Wistar rats were divided into control, diabetic, diabetic+eugenol (4 mg/kg/d, IP), and eugenol-only groups. Diabetes was induced with a single STZ injection (55 mg/kg). After 8 weeks of treatment, fasting blood glucose, serum oxidative stress markers (malondialdehyde [MDA], superoxide dismutase [SOD], glutathione peroxidase [GPx]), testicular histology, and *CatSper1/2* mRNA expression were analyzed.

Results: Eugenol treatment significantly attenuated hyperglycemia in diabetic rats ($P<0.05$). It also mitigated diabetes-induced testicular damage, as shown by histopathological improvement. Biochemically, eugenol reversed oxidative stress by lowering elevated MDA ($P<0.05$) and restoring depleted SOD and GPx activities ($P<0.05$). Crucially, diabetes profoundly downregulated *CatSper1* and *CatSper2* gene expression ($P<0.000$), and eugenol treatment significantly restored their mRNA levels ($P<0.001$).

Conclusion: Eugenol exerts a multifaceted protective effect against diabetic testicular damage by improving glycemic control, reducing oxidative stress, preserving testicular architecture, and restoring the expression of the critical spermatogenic genes: *CatSper1* and *CatSper2*. These findings highlight eugenol's promise as a therapeutic adjunct for managing diabetic male infertility.

* Corresponding Author:

Nasim Hayati Roodbari, Associate Professor.

Address: Department of Biology, SR.C., Islamic Azad University, Tehran, Iran.

Phone: +98 (912) 8145868

E-mail: nasimhayati@yahoo.com



Copyright © 2025 The Author(s).
This is an open access article distributed under the terms of the Creative Commons Attribution License (CC-BY-NC: <https://creativecommons.org/licenses/by-nc/4.0/legalcode.en>), which permits use, distribution, and reproduction in any medium, provided the original work is properly cited and is not used for commercial purposes.

Introduction

Infertility affects approximately 10-25% of reproductive-aged couples globally, equating to 60-80 million couples. Male factors exclusively account for 10-30% of these infertility cases. Among various conditions contributing to declining male fertility, diabetes mellitus (DM) represents a significant concern. As a prevalent chronic disease, DM affected approximately 422 million people worldwide in 2014, posing substantial threats to male reproductive health through multiple pathological mechanisms [1]. Diabetes induces severe oxidative stress in various tissues, including testicular tissue, through chronic hyperglycemia [2]. Diabetes-induced oxidative stress results from an imbalance between reactive oxygen species (ROS) production and endogenous antioxidant defense systems [3]. In testicular tissue, this imbalance can lead to lipid peroxidation, DNA damage, mitochondrial dysfunction, and ultimately, apoptosis of germ cells [4]. Numerous studies have demonstrated that diabetes is associated with significant impairment of sperm quality parameters, including count, motility, and normal morphology [5].

Additionally, reduced levels of sex hormones such as testosterone, luteinizing hormone (LH), and follicle-stimulating hormone (FSH) have been well-documented in diabetic patients. One crucial mechanism by which diabetes affects sperm function involves the disruption of key genes involved in spermatogenesis and sperm maturation [6]. Among these genes, the Cation channel of sperm (*CatSper*) genes are particularly important. *CatSper* channels, comprising four main subunits (*CatSper1-4*), play essential roles in sperm motility, capacitation, and the acrosome reaction. Specifically, *CatSper1* and *CatSper2* serve as fundamental structural components of these channels, and any disruption in their expression can directly impact sperm function [7]. Recent studies have indicated that oxidative stress can affect the expression of these vital genes in spermatogenic cells [8]. *CatSper* channels are selectively permeable to calcium ions and are located in the sperm plasma membrane. These channels activate in response to intracellular pH changes and other factors, regulating calcium influx that is essential for sperm hyperactivation [9]. Impairment of these channel functions is recognized as a significant cause of asthenozoospermia [10]. Recently, researchers have shown growing interest in natural compounds with antioxidant properties as potential therapeutic interventions for oxidative stress-related complications. In this context, eugenol (4-allyl-2-methoxyphenol), the primary phenolic compound in clove essential oil (*Syzygium aro-*

maticum), has garnered significant attention [11]. Eugenol possesses multiple pharmacological properties, including anti-inflammatory, antimicrobial, analgesic, and antioxidant effects.

Various studies have demonstrated that eugenol can protect against oxidative stress through multiple mechanisms, including direct neutralization of free radicals, enhanced activity of antioxidant enzymes such as superoxide dismutase (SOD) and glutathione peroxidase (GPx), increased glutathione levels, and reduced malondialdehyde (MDA) as a lipid peroxidation marker [12, 13]. Additionally, a study demonstrated that eugenol effectively mitigated acrylamide-induced testicular toxicity in rats. The protective mechanism was attributed to modulation of the AMPK/p-AKT/mTOR signaling pathway and to the restoration of blood-testis barrier integrity [14]. Research has demonstrated that eugenol can effectively alleviate intestinal injury caused by the transmissible gastroenteritis virus (TGEV) in pigs. Its protective mechanism acts by suppressing ROS production and subsequently inhibiting the NLRP3/GSDMD-mediated pyroptosis pathway, a form of inflammatory cell death [15]. Although the antioxidant effects of eugenol have been investigated in various models, limited studies have examined its impact on the *CatSper* gene expression under diabetic conditions. Given the importance of these genes in sperm function and the role of oxidative stress in regulating their expression, investigating eugenol's effects on this pathway could reveal novel aspects of its protective mechanisms. Therefore, this study aims to examine the effects of eugenol on oxidative stress indicators (SOD, GPx, MDA) and the expression of *CatSper1* and *CatSper2* genes in streptozotocin (STZ)-induced diabetic rats.

Materials and Methods

Animals and experimental design

This research was an experimental, controlled laboratory study conducted on an animal model. This experimental study used 32 adult male Wistar rats weighing 200-250 g. The animals were housed under standardized laboratory conditions, maintaining a temperature of 23±2 °C, relative humidity of 40-50%, and a 12-hour light-dark cycle, with ad libitum access to standard rodent diet and water. Following three days acclimatization period, the rats were randomly allocated into 4 equal groups (n=8): 1) a healthy control group receiving normal saline; 2) a diabetic control group; 3) a diabetic group treated with eugenol (4 mg/kg/d via gavage) for 8 weeks; and 4) a healthy group receiving the same eugenol treatment regi-

Table 1. Primer sequences

Gene	Sequences
<i>CatSper 1</i>	Forward: TTTACCTGCCTCTTCTCTTCT Reverse: ACCAGGTTGAGGAAGATGAAGT
<i>CatSper 2</i>	Forward: TGGTTGTTGCTTGGTTCC Reverse: TTCCTTGACTGGTTCTCT
<i>GAPDH</i>	Forward: 5'-ACTCTGGTAAAGTGGATATTGTTGC -3' Reverse: 5'-GGAAGATGGTGATGGGATTC -3'



men. Diabetes induction was achieved through a single intraperitoneal injection of (STZ; Sigma-Aldrich) at 55 mg/kg, dissolved in 0.01 M citrate buffer (pH 4.5) [16-18]. Diabetes was confirmed 3 days post-injection by measuring blood glucose levels from the tail vein; rats with glucose concentrations exceeding 250 mg/dL were classified as diabetic.

Sample collection and processing

Upon completion of the 8-week experimental period, all animals were anesthetized using an intraperitoneal injection of ketamine (50 mg/kg) and xylazine (10 mg/kg). Blood samples (3-5 mL) were subsequently collected via cardiac puncture and transferred to sterile tubes. The blood samples were centrifuged at 3500 rpm for 10 minutes to separate serum, which was aliquoted and stored at -80 °C for subsequent biochemical analyses. Following euthanasia, bilateral orchidectomy was performed through a lower abdominal incision. The testes were carefully dissected, cleaned of adhering tissues, and divided for various analyses: One portion was snap-frozen in liquid nitrogen for gene expression studies, while the contralateral testis was processed for histological examination. Fasting blood glucose was measured using a commercial kit (Iran Pars Azmoon).

Assessment of oxidative stress parameters

Oxidative stress was evaluated by measuring key antioxidant enzymes and lipid peroxidation markers in serum samples. SOD and GPx activities were determined using commercial ELISA kits (Anthous, Austria) according to the manufacturer's protocols. Lipid peroxidation was assessed by quantifying MDA levels through the thiobarbituric acid reactive substances method. In this procedure, serum samples were reacted with thiobarbituric acid in an acidic medium, heated for 15 minutes, and the absorbance of the resulting chromogen was measured spectrophotometrically at 532 nm.

RNA extraction and gene expression analysis

Total RNA was extracted from testicular tissue using TRIzol reagent according to the manufacturer's instructions. RNA concentration and purity were determined spectrophotometrically, and samples with A260/A280 ratios of 1.8-2.0 were used for subsequent analysis. Complementary DNA (cDNA) was synthesized using a reverse transcription kit. Quantitative real-time PCR (qRT-PCR) was performed using specific primers for *CatSper1* and *CatSper2*, with *GAPDH* serving as the reference gene (Table 1). The relative expression levels were calculated using the $2^{-(\Delta\Delta C_t)}$ method.

Histological examination

The left testis from each rat was fixed in Bowen's fixative, processed routinely, and embedded in paraffin. Tissue sections (5 μm thick) were stained with hematoxylin and eosin (H&E). For each testis, 50 randomly selected round seminiferous tubules were examined under a light microscope. The diameter of the seminiferous tubules and the height of the germinal epithelium were measured using image analysis software. A quantitative assessment of spermatogenic function was performed using the Johnsen scoring system (score 1-10), with higher scores indicating complete spermatogenesis and normal tubular epithelium.

Statistical analysis

All quantitative data are presented as Mean±SD. Statistical analyses were performed in SPSS software, version 18 (SPSS Inc., Chicago, IL, USA). Intergroup comparisons were conducted using a one-way analysis of variance (ANOVA), with post hoc comparisons performed using the least significant difference (LSD) test. Statistical significance was defined as a P<0.05 for all analyses.

Results

Fasting blood glucose levels

Analysis of fasting blood glucose levels revealed significant variations among the experimental groups throughout the study period. Before diabetes induction, all animals exhibited normal fasting blood glucose levels within the physiological range, with no statistically significant differences observed between groups ($P > 0.05$), confirming comparable baseline metabolic status. Three days after STZ administration, diabetic induction groups (diabetic and diabetic+eugenol) showed a significant increase in fasting blood glucose levels compared with the healthy control group ($P < 0.05$). At the conclusion of the 8-week experimental period, the diabetic group maintained significantly elevated blood glucose levels compared to the control group ($P < 0.05$). Importantly, the diabetic+eugenol group showed a statistically significant reduction in blood glucose levels compared to the untreated diabetic group ($P < 0.05$) (Table 2).

Histopathological examination results

Microscopic evaluation of testicular tissue revealed significant differences among the experimental groups. In the diabetic group receiving eugenol, the seminiferous tubules showed only minor structural alterations compared with those in the control groups. Notably, significant tissue disintegration and degenerative changes in the germinal epithelium were not clearly observable. The germ cells maintained their normal morphological characteristics, and the seminiferous tubules appeared regularly arranged with approximately rounded contours. The interstitial spaces surrounding the seminiferous tubules were not empty, and no signs of inflammatory infiltration were detected. The basement membranes of all seminiferous tubules appeared continuous and intact when compared to the diabetic control group. While a limited number of cells within each seminiferous tubule showed evidence of sloughing, no marked atrophy of the

seminiferous tubules was observed. In the group receiving eugenol alone, all histological features observed under light microscopy were comparable to those described in the healthy control group. Germ cells at various stages of development were clearly visible adjacent to the basement membrane and within the tubular lumina, indicating normal spermatogenic activity (Figure 1).

Evaluation of seminiferous tubules based on Johnson score, diameter, and epithelial thickness

Evaluation of seminiferous tubules using the Johnson score revealed that the mean Johnson score, seminiferous tubule diameter, and tubular epithelial thickness were significantly reduced in the diabetic control group compared with the other experimental groups ($P < 0.05$). Furthermore, in the eugenol-treated diabetic groups, the mean Johnson score, seminiferous tubule diameter, and tubular epithelial thickness were significantly higher than in the diabetic control group. However, these values remained lower than those in the healthy control group ($P < 0.05$). On the other hand, the group receiving eugenol alone showed no significant change in the mean Johnson score, seminiferous tubule diameter, or tubular epithelial thickness compared to the healthy control group (Table 3).

Serum oxidative stress parameter levels

MDA levels

Evaluation of serum MDA levels across the study groups revealed significant differences. The diabetic control group exhibited a statistically significant increase in MDA concentration compared to the healthy control group ($P < 0.05$). Conversely, serum MDA levels were significantly lower in all eugenol-treated groups than in the diabetic control group ($P < 0.05$). However, despite this improvement, MDA levels in the eugenol-treated diabetic groups remained significantly elevated relative to the healthy control group ($P < 0.05$) (Table 4).

Table 2. Fasting blood glucose levels (mg/dL)

Group	Mean±SD		
	Before Diabetes Induction	Three Days After Induction	End of Study (8 Weeks)
Control	94.5±5.34	102.42±7.25	92.4±5.34
Diabetic	98.2±2.6	325.4±4.07*	357.6±15.73*
Diabetic + eugenol	96.3±3.89	305.5±4.03*	180.2±3.2**
Eugenol	94.25±2.4	92.8±4.7	91.5±4.05

*Significant compared to the control group ($P < 0.05$), **Significant compared to the diabetic group ($P < 0.05$).

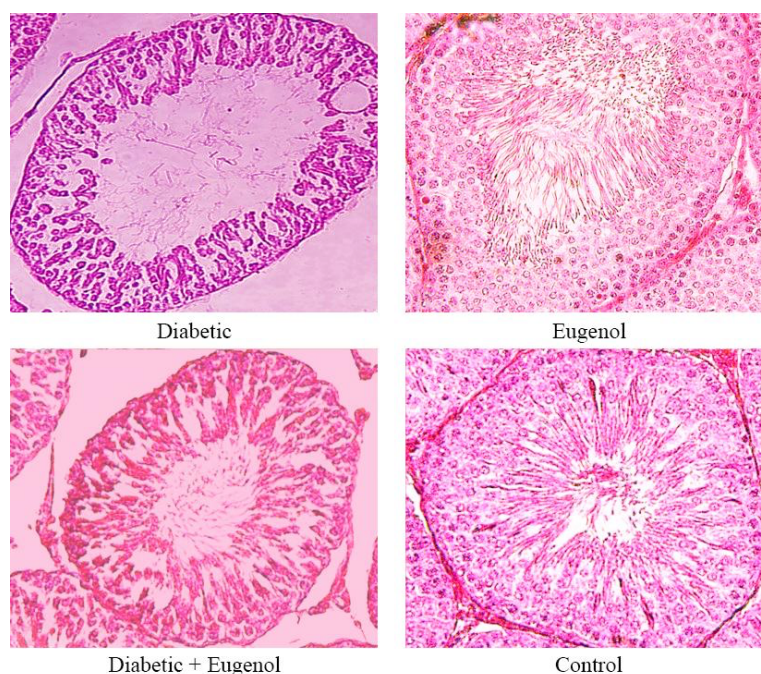


Figure 1. Representative picture of testis histology in different study groups



Note: Diabetic group in which severe testicular damage was noted; control group in which normal testicular architecture was seen; diabetic group treated with eugenol, in which there was an improvement in the seminiferous tubule structure (stained with H&E, scale bar: $\times 400$).

SOD levels

Assessment of serum SOD activity showed a significant decrease in the diabetic control group compared with the healthy control group ($P < 0.05$). Treatment with eugenol resulted in a significant increase in serum SOD levels in all treated groups compared to the untreated diabetic group ($P < 0.05$). Nonetheless, SOD activity in the eugenol-treated diabetic groups remained significantly lower than that observed in the healthy control group ($P < 0.05$) (Table 4).

GPx levels

Analysis of serum GPx activity indicated a significant reduction in the diabetic control group compared to the healthy control group ($P < 0.05$). A significant increase in serum GPx levels was observed in the eugenol-treated groups when compared to the diabetic control group ($P < 0.05$). However, similar to the pattern seen with SOD, GPx activity in the eugenol-treated diabetic groups was still significantly lower than that in the healthy control group ($P < 0.05$) (Table 4).

Table 3. Comparing Mean \pm SD of Johnson score, seminiferous tubule diameter, and tubular epithelial thickness in the study groups

Group	Mean \pm SD		
	Mean Johnson Score	Seminiferous Tubule Diameter (μm)	Epithelial Thickness (μm)
Healthy control	9.7 \pm 0.46	252.42 \pm 4.25	65.5 \pm 1.25
Diabetic	4.4 \pm 0.17*	145.11 \pm 2.57*	31.5 \pm 2.13*
Diabetic + eugenol	7.25 \pm 0.44**	188.5 \pm 3.23**	52.5 \pm 2.15**
Eugenol	9.5 \pm 0.34	255.22 \pm 1.7	66.03 \pm 1.05



*Indicates significance compared to the healthy control group. **Indicates significance compared to the diabetic group.

Table 4. Effect of eugenol on the levels of SOD, GPx, and MDA in the rats' serum after STZ-induced diabetes

Group	Mean±SD		
	SOD (U/mL)	GPx (U/mL)	MDA (nmol/mL)
Control	1.65±0.21	2.3±0.15	0.58±0.08
Diabetic	0.6±0.11 [*]	0.75±0.13 [*]	2.2±0.03 [*]
Diabetic + eugenol	1.2±0.18 ⁺	1.4±0.16 ⁺	1.6±0.07 ⁺
Eugenol	1.68±0.25 [*]	2.25±0.125 [*]	0.55±0.08 [*]



Abbreviations: SOD: Superoxide dismutase; GPx: Glutathione peroxidase; MDA: Malondialdehyde.

^{*}P<0.05 compared to the control group, ⁺P<0.05 compared to the diabetic control group.

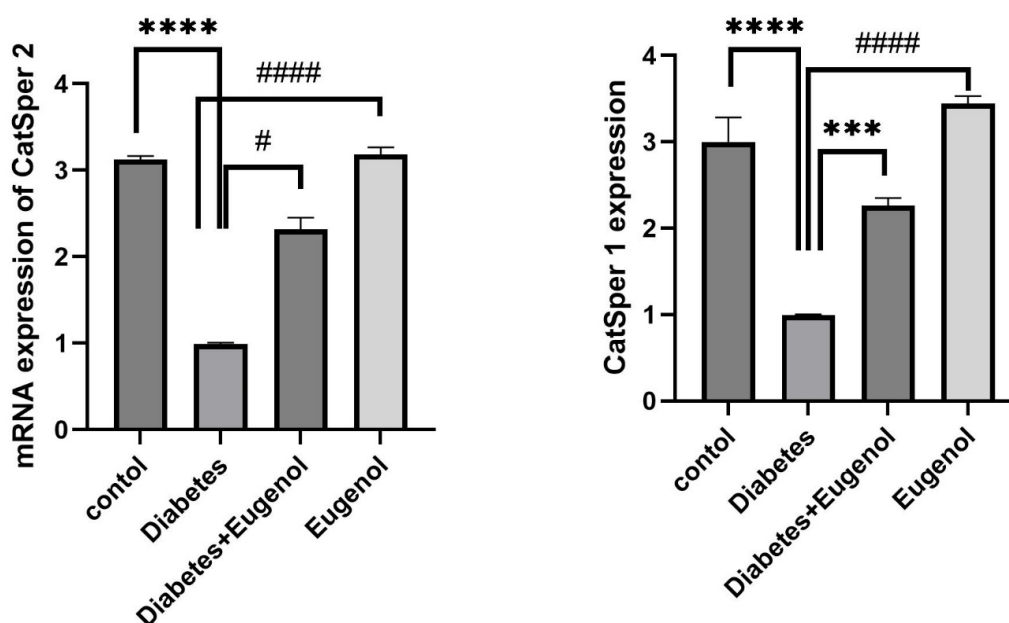
CatSper1 and *CatSper2* gene expression

Quantitative real-time PCR analysis revealed significant alterations in mRNA expression levels of the sperm-specific cation channel genes, *CatSper1* and *CatSper2*, in testicular tissue across the experimental cohorts.

Evaluation of the *CatSper1* gene expression demonstrated a substantial downregulation in the Diabetic group relative to the normoglycemic Control group (P<0.001; **Figure 1A**). Therapeutic intervention with eugenol in the diabetic+eugenol group significantly mitigated this suppression, resulting in a marked elevation in *CatSper1* transcript levels compared with the untreated

diabetic cohort (P<0.001). Notably, the expression in the eugenol monotherapy group did not differ significantly from that in the control group.

A congruent expression profile was observed for the *Catsper2* gene (**Figure 1B**). Diabetes induction precipitated a profound reduction in *CatSper2* mRNA abundance in the diabetic control group compared to the healthy controls (P<0.001). Eugenol treatment conferred a significant restorative effect, with the diabetic+eugenol group exhibiting markedly higher *CatSper2* expression than the untreated diabetic group (P<0.01) (**Figure 2**).

**Figure 2.** Relative mRNA expression levels of *CatSper* genes in testicular tissue of experimental groups

^{***}P<0.001, ^{****}P<0.0001, [#]P<0.01, ^{####}P<0.0001.



Discussion

The present study provides compelling evidence that eugenol, a primary bioactive component of clove oil renowned for its broad-spectrum antioxidant, antimicrobial, antifungal, and antiviral properties [19], confers significant protection against diabetes-induced testicular damage, primarily by modulating oxidative stress parameters. Our quantitative histomorphometric analysis, utilizing the Johnsen scoring system, unequivocally revealed substantial testicular impairment in the diabetic cohort. This finding was evidenced by a marked reduction in the mean Johnsen score, seminiferous tubule diameter, and epithelial height compared to the healthy control group ($P < 0.05$). Critically, eugenol intervention in diabetic rats significantly ameliorated these structural deficits, leading to a notable increase in all three morphometric parameters relative to the untreated diabetic group ($P < 0.05$). However, the values remained intermediate between the diabetic and healthy control levels, indicating a partial but significant restoration of testicular function.

Our biochemical findings further solidify the central role of oxidative stress in the pathogenesis of diabetes-induced testicular injury. We observed that the diabetic state significantly elevated MDA levels, a robust marker of lipid peroxidation, while concurrently reducing the activities of the key antioxidant enzymes, SOD and GPx. The observed oxidative imbalance is consistent with a substantial body of previous research demonstrating that diabetes potently enhances ROS production, inducing a state of significant oxidative stress that depletes endogenous antioxidant defenses and accelerates cellular damage [20]. The diabetic condition precipitates a profound redox imbalance, characterized by the excessive generation of free radical species, including superoxide, hydroxyl, and peroxy radicals. This oxidative surge actively accelerates membrane lipid peroxidation while simultaneously depleting the body's endogenous antioxidant defenses. In our investigation, therapeutic administration of eugenol effectively counteracted these pathological alterations. Eugenol treatment significantly attenuated lipid peroxidation, as demonstrated by reduced MDA levels, and concurrently enhanced the activities of SOD and GPx, thereby fortifying the cellular antioxidant defense system. These results align closely with the established literature, confirming that exogenous antioxidant compounds can effectively mitigate the destructive impact of oxidative stress on the delicate testicular microenvironment and spermatogenic function [21, 22]. Our findings align with studies on other phytochemicals, such as piperine, which similarly demonstrated protection against chemical-induced testicular

damage by counteracting oxidative stress and its downstream effects [23]. The specific antioxidant efficacy of eugenol, documented here, characterized by reduced lipid peroxidation and enhanced antioxidant enzyme activities, directly corroborates earlier findings by Barghi et al [24].

Furthermore, eugenol administration at our tested dosage demonstrated a highly favorable safety profile, inducing no adverse histopathological alterations in the testicular tissue of healthy animals. This finding corroborates earlier safety assessments of this compound [24]. It is further supported by the work of Moghimian et al., who, in their 2017 study, demonstrated that administering a clove extract containing over 90% eugenol to healthy rats did not induce any testicular tissue disorders, thereby confirming its safety [22].

The protective mechanism of eugenol appears to involve the suppression of oxidative stress-induced apoptotic pathways. Substantial evidence indicates that diabetes-induced oxidative stress is a potent activator of both the intrinsic and extrinsic apoptotic pathways in testicular tissue [20]. Externally, ROS can promote the extrinsic pathway via TNF- α and FasL binding to their receptors (TNFR1 and Fas), initiating caspase-8 and subsequently executing caspases-3/7 [25, 26]. Concurrently, the intrinsic pathway is activated through mitochondrial cytochrome c release, leading to apoptosome formation and caspase-9 activation [27]. This finding showed that diabetes activates these caspase cascades and that increased caspase-3 significantly contributes to testicular apoptosis [28]. The consistency between our findings and other antioxidant studies underscores their therapeutic potential. Shoorei et al. showed that carvedilol ameliorates oxidative stress and germ cell apoptosis in diabetic rat testes [29]. Similarly, Al-Hashem et al. and Hartley et al. reported protective effects of vitamins E/C and melatonin, respectively, against hypoxia-induced impairment of reproductive function [30, 31]. At the same time, Moghimian et al. demonstrated vitamin C's efficacy against torsion-induced testicular damage [21].

The robust antioxidant efficacy of eugenol observed in our model is strongly corroborated by recent literature. Our findings are strongly supported by the work of Chilikoti et al. who demonstrated that eugenol effectively mitigates diabetes-induced oxidative stress and cellular damage in rat testicular tissue [32]. Furthermore, while our study focused on oxidative stress and gene expression, Rad et al. further elucidated the protective pathway, providing direct molecular evidence that eugenol treatment in diabetic rats favorably modulates key apoptotic

regulators [18]. This collective evidence solidifies eugenol's role as a multifaceted therapeutic agent against diabetic testicular damage.

Crucially, we provide compelling evidence that experimental diabetes significantly downregulates the expression of the sperm-specific cation channel genes *CatSper1* and *CatSper2*, a suppression effectively counteracted by eugenol. This issue offers a vital molecular insight into the mechanisms underlying diabetic infertility. This finding aligns with a 2023 study on diabetic mice, which found that diabetes simultaneously damages sperm DNA, chromatin, morphology, and CatSper protein expression, providing a comprehensive explanation for clinical infertility in diabetic men [33].

The observed CatSper downregulation provides a molecular basis for the impaired sperm motility (asthenozoospermia) seen in diabetic males, as the CatSper channel complex in the sperm flagellum is indispensable for calcium influx during hyperactivation, a motility pattern essential for fertilization [34]. Our finding corroborates proteomic research by Brewis et al. which identified significant alterations in sperm ion channel proteins under diabetic conditions [35]. Notably, eugenol did not alter basal CatSper expression in non-diabetic animals, indicating a targeted action against pathological dysregulation without disrupting physiological expression, aligning with its established safety profile [36].

This study was limited to two *CatSper* genes and did not assess other channel subunits or direct sperm functional parameters, such as calcium influx or motility. Future research should investigate other CatSper subunits, eugenol's direct effect on channel function and sperm hyperactivation, and conduct longer-term studies to confirm effects on fertility and validate these mechanisms in other models.

Conclusion

The present study compellingly demonstrates that eugenol, the primary compound in clove oil, protects against diabetes-induced testicular damage through multiple mechanisms. Our findings revealed that diabetes causes testicular tissue injury by inducing oxidative stress, increasing lipid peroxidation, and decreasing the activity of antioxidant enzymes SOD and GPx. Eugenol treatment effectively reversed these pathological changes. This compound protected the tissue from damage by reducing oxidative stress and enhancing the activity of antioxidant enzymes. Specifically, eugenol restored the expression of *CatSper1* and *CatSper2* genes, which were

significantly downregulated in diabetes. These genes are crucial for the normal function of sperm calcium channels and sperm motility. Given eugenol's efficacy in repairing the molecular, biochemical, and tissue damage caused by diabetes, along with its favorable safety profile, this compound can be considered a promising therapeutic option for male reproductive complications of diabetes.

Ethical Considerations

Compliance with ethical guidelines

The experimental protocol received formal approval from the Ethics Committee of [Islamic Azad University](#) (162474155) before commencement.

Funding

This research did not receive any grant from funding agencies in the public, commercial, or non-profit sectors.

Authors contribution's

Investigation, formal analysis, and writing the original draft: Maryam Shaeghi Rad; Conceptualization, project administration, review, and editing: Nasim Hayati Roodbari; Data collection: Amir Afshin Khaki; Resources: Nasim Hayati Roodbari and Amir Afshin Khaki; Methodology: Maryam Shaeghi Rad and Akram Eidi; Validation: Akram Eidi and Amir Afshin Khaki; Final approval: All authors; Supervision: Akram Eidi, Amir Afshin Khaki, and Nasim Hayati Roodbari.

Conflict of interest

The authors declared no conflict of interest.

Acknowledgements

The authors would like to express their sincere gratitude to the staff of the Department of Biology at the [Science and Research Branch, Islamic Azad University](#), and the Department of Anatomical Sciences at [Tabriz University of Medical Sciences](#) for providing the necessary facilities and support to conduct this research.

References

- [1] Temidayo SO, Du Plessis SS. Diabetes mellitus and male infertility. *Asian Pacific J Reproduct*. 2018;7(1):6-14. [DOI:10.4103/2305-0500.220978] [PMID]
- [2] Mohasseb M, Ebied S, Yehia MA, Hussein N. Testicular oxidative damage and role of combined antioxidant supplementation in experimental diabetic rats. *J Physiol Biochem*. 2011; 67(2):185-94. [DOI:10.1007/s13105-010-0062-2] [PMID]
- [3] Asmat U, Abad K, Ismail K. Diabetes mellitus and oxidative stress-A concise review. *Saudi Pharm J*. 2016; 24(5):547-53. [DOI:10.1016/j.jsps.2015.03.013] [PMID]
- [4] Asadi N, Bahmani M, Kheradmand A, Rafieian-Kopaei M. The impact of oxidative stress on testicular function and the role of antioxidants in improving it: A review. *J Clin Diagn Res*. 2017; 11(5):IE01-5. [DOI:10.7860/JCDR/2017/23927.9886] [PMID]
- [5] Lotti F, Maggi M. Effects of diabetes mellitus on sperm quality and fertility outcomes: Clinical evidence. *Andrology*. 2023; 11(2):399-416. [DOI:10.1111/andr.13342] [PMID]
- [6] Huang R, Chen J, Guo B, Jiang C, Sun W. Diabetes-induced male infertility: Potential mechanisms and treatment options. *Mol Med*. 2024; 30(1):11. [DOI:10.1186/s10020-023-00771-x] [PMID]
- [7] Singh AP, Rajender S. CatSper channel, sperm function and male fertility. *Reproduct Biomed Online*. 2015; 30(1):28-38. [DOI:10.1016/j.rbmo.2014.09.014] [PMID]
- [8] Afsar T, Razak S, Trembley JH, Khan K, Shabbir M, Almajwal A, et al. Prevention of testicular damage by indole derivative MMINA via upregulated StAR and CatSper channels with coincident suppression of oxidative stress and inflammation: In silico and in vivo validation. *Antioxidants*. 2022; 11(10):2063. [DOI:10.3390/antiox11102063] [PMID]
- [9] Sun XH, Zhu YY, Wang L, Liu HL, Ling Y, Li ZL, et al. The Catsper channel and its roles in male fertility: A systematic review. *Reprod Biol Endocrinol*. 2017; 15(1):65. [DOI:10.1186/s12958-017-0281-2] [PMID]
- [10] Jin ZR, Fang D, Liu BH, Cai J, Tang WH, Jiang H, et al. Roles of CatSper channels in the pathogenesis of asthenozoospermia and the therapeutic effects of acupuncture-like treatment on asthenozoospermia. *Theranostics*. 2021; 11(6):2822-44. [DOI:10.7150/thno.51869] [PMID]
- [11] Ma L, Liu J, Lin Q, Gu Y, Yu W. Eugenol protects cells against oxidative stress via Nrf2. *Exp Ther Med*. 2021; 21(2):107. [DOI:10.3892/etm.2020.9539] [PMID]
- [12] Nisar MF, Khadim M, Rafiq M, Chen J, Yang Y, Wan CC. Pharmacological properties and health benefits of eugenol: A comprehensive review. *Oxid Med Cell Longev*. 2021; 2021:2497354. [DOI:10.1155/2021/2497354] [PMID]
- [13] Barboza JN, da Silva Maia Bezerra Filho C, Silva RO, Medeiros JVR, de Sousa DP. An overview on the anti-inflammatory potential and antioxidant profile of eugenol. *Oxid Med Cell Longev*. 2018; 2018:3957262. [DOI:10.1155/2018/3957262] [PMID]
- [14] Saleh DO, Baraka SM, Jaleel GAA, Hassan A, Ahmed-Farid OA. Eugenol alleviates acrylamide-induced rat testicular toxicity by modulating AMPK/p-AKT/mTOR signaling pathway and blood-testis barrier remodeling. *Sci Rep*. 2024; 14(1):1910. [DOI:10.1038/s41598-024-52259-1] [PMID]
- [15] Wang K, Chen D, Yu B, He J, Mao X, Huang Z, et al. Eugenol alleviates TGEV-induced intestinal injury via suppressing ROS/NLRP3/GSDMD-dependent pyroptosis. *J Agric Food Chem*. 2023; 71(3):1477-87. [DOI:10.1021/acs.jafc.2c05833] [PMID]
- [16] Moghimian M, Abtahi-Evari SH, Shokoohi M, Amiri M, Soltani M. Effect of syzygium aromaticum (clove) extract on seminiferous tubules and oxidative stress after testicular torsion in adult rats. *Physiol Pharmacol*. 2017; 21(4):343-50. [Link]
- [17] Abtahi-Eivari SH, Shokoohi M, Ghorbani M, Halimi M, Hajizadeh H, Pourlak T, et al. Effects of Hydroalcoholic Extracts of Cloves (*Syzygium aromaticum*) on the Serum Biomarkers, Antioxidant Status, and Histopathological Changes of Kidneys in Diabetic Rats. *Crescent J Med Biol Sci*. 2021; 8(4):269-75. [Link]
- [18] Rad MS, Roodbari NH, Khaki AA, Amidi F, Eidi A. Eugenol reduces oxidative stress and modulates BAX/BCL-2 in testes of diabetic rats. *Crescent J Med Biol Sci*. 2025; 12(2):110-8. [DOI:10.34172/cjmb.2025.5022]
- [19] Batiha GE, Alkazmi LM, Wasef LG, Beshbishy AM, Nadwa EH, Rashwan EK. *Syzygium aromaticum* L. (Myrtaceae): Traditional uses, bioactive chemical constituents, pharmacological and toxicological activities. *Biomolecules*. 2020; 10(2):202. [DOI:10.3390/biom10020202] [PMID]
- [20] Shoorei H, Khaki A, Shokoohi M, Khaki AA, Alihemmati A, Moghimian M, et al. Evaluation of carvacrol on pituitary and sexual hormones and their receptors in the testicle of male diabetic rats. *Hum Exp Toxicol*. 2020; 39(8):1019-30. [DOI:10.1177/0960327120909525] [PMID]
- [21] Moghimian M, Soltani M, Abtahi H, Shokoohi M. Effect of vitamin C on tissue damage and oxidative stress following tunica vaginalis flap coverage after testicular torsion. *J Pediatr Surg*. 2017; 52(10):1651-5. [DOI:10.1016/j.jpedsurg.2017.07.001] [PMID]
- [22] Celik E, Oguzturk H, Sahin N, Turtay MG, Oguz F, Ciftci O. Protective effects of hesperidin in experimental testicular ischemia/reperfusion injury in rats. *Arch Med Sci*. 2016; 12(5):928-34. [DOI:10.5114/aoms.2015.47697] [PMID]
- [23] Fani F, Hosseinimehr SJ, Zargari M, Mirzaei M, Karimpour Malekshah A, Talebpour Amiri F. Piperine mitigates oxidative stress, inflammation, and apoptosis in the testicular damage induced by cyclophosphamide in mice. *J Biochem Mol Toxicol*. 2024; 38(4):e23696. [DOI:10.1002/jbt.23696] [PMID]
- [24] Barghi B, Shokoohi M, Khaki AA, Khaki A, Moghimian M, Soltani M. Eugenol improves tissue damage and oxidative stress in adult female rats after ovarian torsion/detorsion. *J Obstet Gynaecol*. 2021; 41(6):933-8. [DOI:10.1080/01443615.2020.1816938] [PMID]
- [25] Zimmermann KC, Bonzon C, Green DR. The machinery of programmed cell death. *Pharmacol Ther*. 2001; 92(1):57-70. [DOI:10.1016/S0163-7258(01)00159-0] [PMID]
- [26] Redza-Dutordoir M, Averill-Bates DA. Activation of apoptosis signalling pathways by reactive oxygen species. *Biochim Biophys Acta*. 2016; 1863(12):2977-92. [DOI:10.1016/j.bbamer.2016.09.012] [PMID]

- [27] Theas MS, Rival C, Dietrich SJ, Guazzone VA, Lustig L. Death receptor and mitochondrial pathways are involved in germ cell apoptosis in an experimental model of autoimmune orchitis. *Hum Reprod.* 2006; 21(7):1734-42. [DOI:10.1093/humrep/del066] [PMID]
- [28] Xu R, Wang F, Zhang Z, Zhang Y, Tang Y, Bi J, et al. Diabetes-induced autophagy dysregulation engenders testicular impairment via oxidative stress. *Oxid Med Cell Longev.* 2023; 2023:4365895. [DOI:10.1155/2023/4365895] [PMID]
- [29] Shoorei H, Khaki A, Khaki AA, Hemmati AA, Moghimian M, Shokoohi M. The ameliorative effect of carvacrol on oxidative stress and germ cell apoptosis in testicular tissue of adult diabetic rats. *Biomed Pharmacother.* 2019; 111:568-78. [DOI:10.1016/j.biopha.2018.12.054] [PMID]
- [30] Hartley R, Castro-Sánchez R, Ramos-Gonzalez B, Bustos Obregón E. Rat spermatogenesis damage in intermittent hypobaric hypoxia and the protective role of melatonin. *Int J Morphol.* 2009; 27(4):1275-84. [DOI:10.4067/S0717-95022009000400049]
- [31] Al-Hashem FH. Role of vitamins E and C in mitigating hypoxia-and exhaustive exercise-induced aberrant stem cell factor expression and impaired reproductive function in male Wistar rats. *Saudi Med J.* 2013; 34(4):354-63. [PMID]
- [32] Chilukoti SR, Sahu C, Jena G. Protective role of eugenol against diabetes-induced oxidative stress, DNA damage, and apoptosis in rat testes. *J Biochem Mol Toxicol.* 2024; 38(1):e23593. [DOI:10.1002/jbt.23593] [PMID]
- [33] Khordad E, Nikravesh MR, Jalali M, Fazel A, Sankian M, Alipour F. Evaluation of sperm chromatin/DNA integrity, morphology, and Catsper expression on diabetic C57BL/6 mice. *Cell Mol Biol.* 2022; 68(2):8-18. [DOI:10.14715/cmb/2022.68.2.2] [PMID]
- [34] Ren D, Navarro B, Perez G, Jackson AC, Hsu S, Shi Q, et al. A sperm ion channel required for sperm motility and male fertility. *Nature.* 2001; 413(6856):603-9. [DOI:10.1038/35098027] [PMID]
- [35] Brewis IA, Gadella BM. Sperm surface proteomics: From protein lists to biological function. *Mol Hum Reprod.* 2010; 16(2):68-79. [DOI:10.1093/molehr/gap077] [PMID]
- [36] Kamatou GP, Vermaak I, Viljoen AM. Eugenol—from the remote Maluku Islands to the international market place: A review of a remarkable and versatile molecule. *Molecules.* 2012; 17(6):6953-81. [DOI:10.3390/molecules17066953] [PMID]